EPOS™
Electronic Presentation Online System

European Society of Radiology

The lifesaving phone call: Acute aortic syndromes

Poster No.: C-2065

Congress: ECR 2017

Type: Educational Exhibit

Authors: D. Roriz[1], I. Abreu[2], R. Rodrigues[3], M. Moreira[3], P. Belo Soares[4], F. Caseiro Alves[5]; [1]Guimarães/PT, [2]Porto/PT, [3]Coimbra/PT, [4]Mem Martins/PT, [5]Coimbra, Coimbra/PT

Keywords: Fistula, Dissection, Aneurysms, Diagnostic procedure, CT-Angiography, CT, Thorax, Arteries / Aorta, Abdomen

DOI: 10.1594/ecr2017/C-2065

Any information contained in this pdf file is automatically generated from digital material submitted to EPOS by third parties in the form of scientific presentations. References to any names, marks, products, or services of third parties or hypertext links to third-party sites or information are provided solely as a convenience to you and do not in any way constitute or imply ECR's endorsement, sponsorship or recommendation of the third party, information, product or service. ECR is not responsible for the content of these pages and does not make any representations regarding the content or accuracy of material in this file.
As per copyright regulations, any unauthorised use of the material or parts thereof as well as commercial reproduction or multiple distribution by any traditional or electronically based reproduction/publication method ist strictly prohibited.
You agree to defend, indemnify, and hold ECR harmless from and against any and all claims, damages, costs, and expenses, including attorneys' fees, arising from or related to your use of these pages.
Please note: Links to movies, ppt slideshows and any other multimedia files are not available in the pdf version of presentations.
www.myESR.org

Learning objectives

- Describe the different aortic syndromes, their pathophysiology and imaging presentation;

- Optimizing the CT technique for the diagnosis and evaluation of the acute aortic syndromes;

- Present their prognosis, treatment modalities and main complications.

Background

Acute aortic syndromes (AAS) are a group of life-threatening conditions encompassing: aortic dissection, intramural hematoma and atherosclerotic ulcer (Fig. 1). Excruciating pain is the main symptom but doesn't allow the distinction between the different aetiologies. Besides, other pathologies such as pulmonary embolism might have a similar clinical presentation and should also be excluded in many of these patients. This clinically overlap and the high mortality explains the enormous relevance of imaging methods in their diagnosis and therapeutic planning. In this review, we will focus non-traumatic AAS.

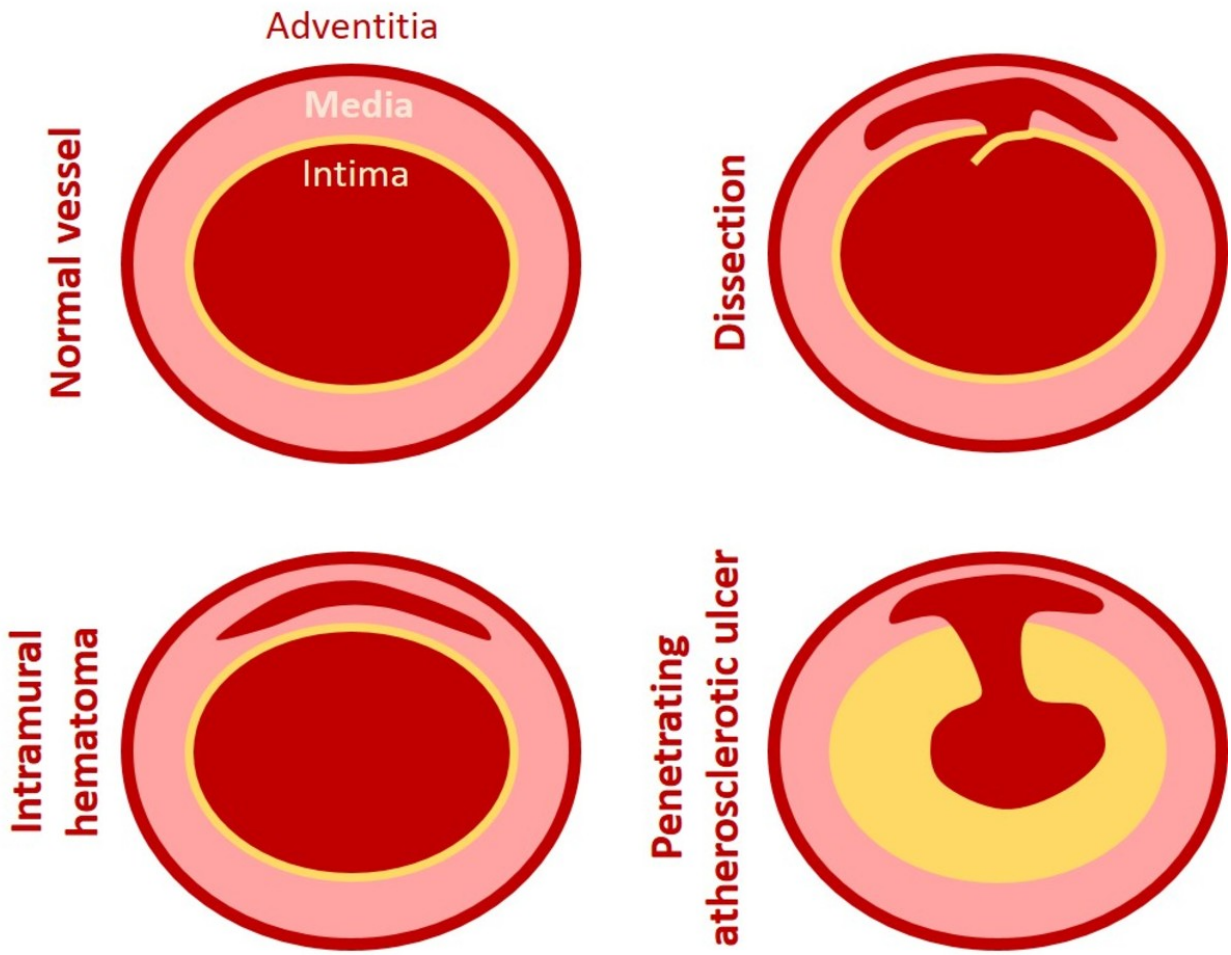

Fig. 1: Pathophysiology of acute aortic syndromes. In aortic dissection there is rupture of the intima, with blood accessing the medial layer and creating a false lumen. Patients with intramural hematoma have a collection of blood in the media, but no discontinuity is seen in the intimal layer of the aorta. Penetrating atherosclerotic ulcer develop in patients with advanced atherosclerosis after erosion of the intima in a plaque.
References: Radiologia, Centro Hospitalar e Universitário de Coimbra - Guimarães/PT

The MDCT is considered the gold standard for evaluating AAS due to its universal availability, time performance and accuracy in the diagnosis. It has a sensitivity around 96-100% and a specificity of 87-99%. Ecocardiography and MRI might also have a role, but their use in the suspicion of AAS has recently decreased with the wide use of contrast-enhanced CT. Ecocardiography might be a first line technique, since it allows a bedside diagnosis. MRI is now reserved as an alternative to CT in patients with non-acute presentation.

Aortic anatomy

The ascending thoracic aorta extends from the aortic root to the origin of the right brachiocephalic artery (Fig. 2). The aortic root is the first segment of the ascending aorta, containing: the valve, the annulus and the sinuses.

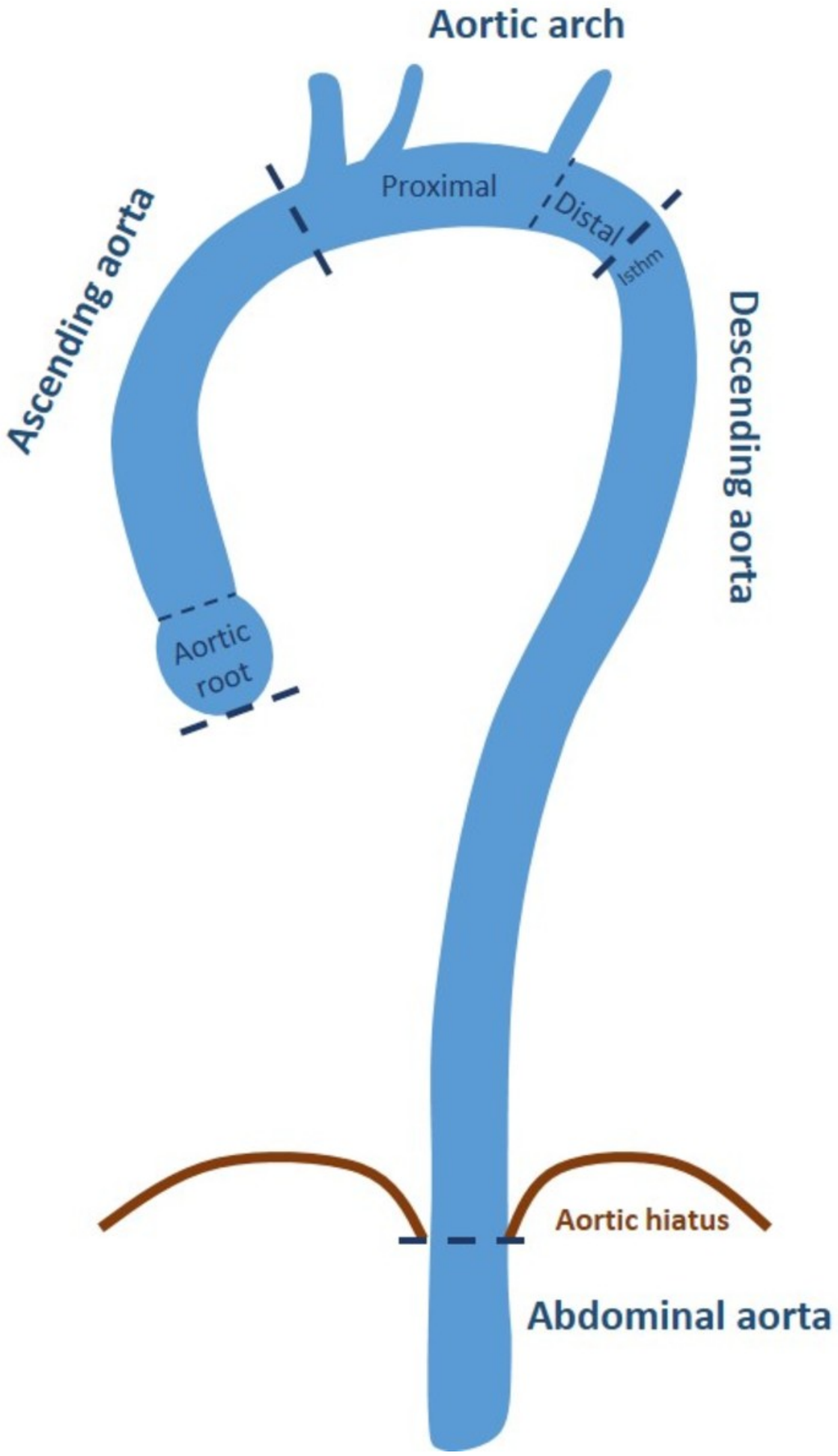
Aortic arch
Proximal
Distal
Isthm
Ascending aorta
Descending aorta
Aortic root
Aortic hiatus
Abdominal aorta

Fig. 2: Ascending thoracic aorta extends from the root to the origin of the right brachiocephalic artery. The aortic root is the first segment of the ascending aorta, containing: the valve, the annulus and the sinuses. Aortic arch starts at the level of the right brachiocephalic artery with its distal boundary being the attachment of the ligamentum arteriosum. The arch may then be subdivided in proximal (from the right brachiocephalic artery to the left subclavian artery) and distal (until the ligamentum arteriosum attachment). The descending aorta extends from the attachment of the ligamentum arteriosum to the aortic hiatus of the diaphragm. The isthmus is narrower portion of the proximal descending aorta.
References: Radiologia, Centro Hospitalar e Universitário de Coimbra - Guimarães/PT

The aortic arch starts at the origin of the right brachiocephalic artery with its distal boundary being the attachment of the ligamentum arteriosum. The arch may then be subdivided in the proximal (from the right brachiocephalic artery to the left subclavian artery) and distal segments (from the left subclavian artery).

The descending aorta extends from the attachment of the ligamentum arteriosum to the aortic hiatus of the diaphragm. The isthmus is the narrower portion of the proximal descending aorta.

CT protocol

At our institution, the CT protocol used for patients with a clinical suspicion of AAS is based on an EKG-gated 64 slice multidetector CT scanner. Axial reconstruction with 1-2 mm thickness and MPRs in the coronal, sagittal and oblique are used.

A non-enhanced acquisition of the thoracic aorta is firstly performed which might be essential for the detection of intramural hematomas. This is followed by a contrast-enhanced scan. The cardiac output is frequently reduced in these patients and thus the arrival time of contrast to the aorta, might be delayed so we recommend the use of bolus tracking with 100 HU threshold at the level of the aortic arch. Both arterial and venous phase are recommended, from the lung vertices (imaging the origin of the supra-aortic trunks) to the pubic symphysis (encompassing the aortic bifurcation). Contrast injection is done in the right arm in order to minimize the contrast artifacts in the aortic arch that might not allow the identification of the intimal flap.

Images for this section:

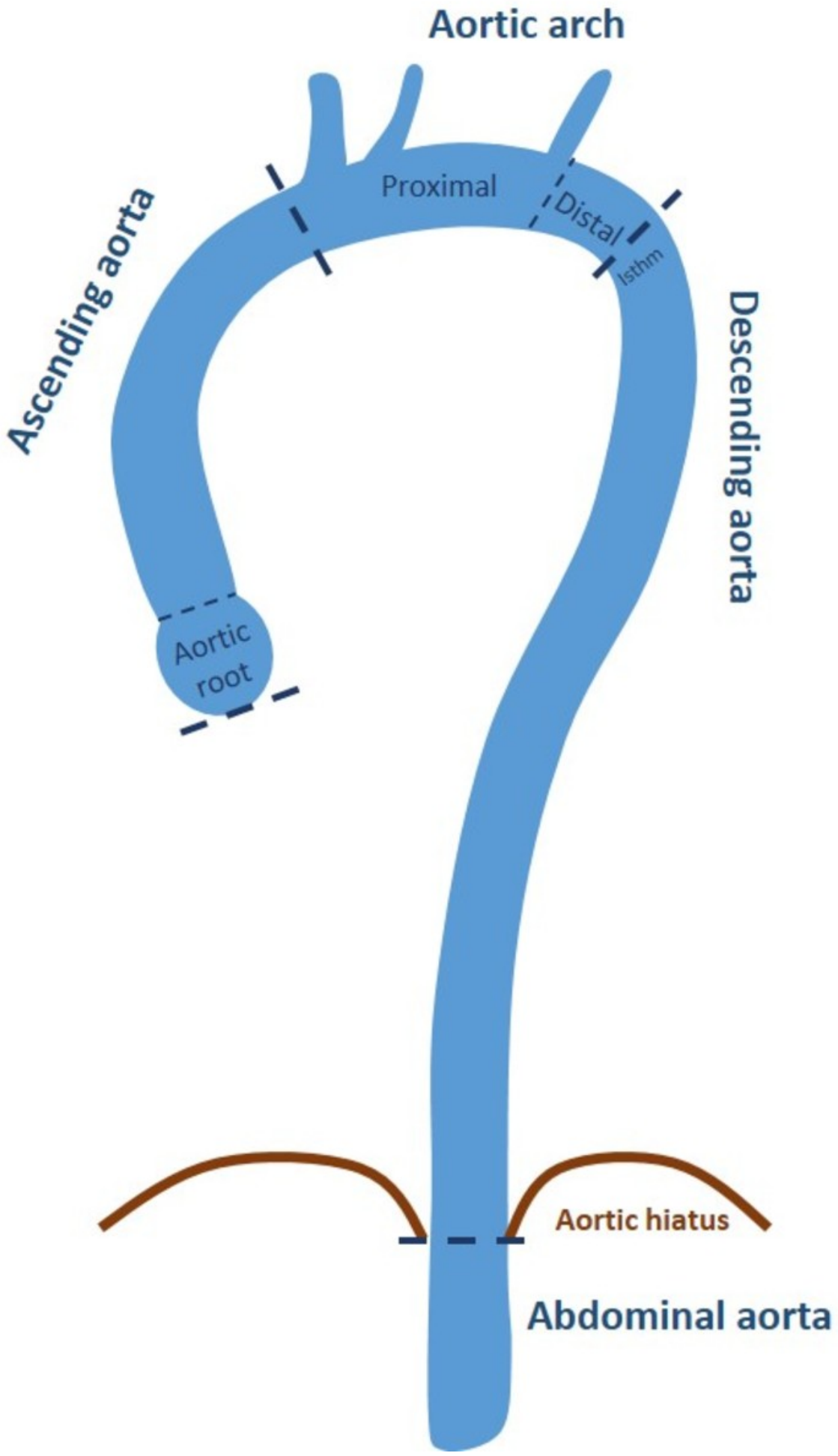
Aortic arch
Proximal
Distal
Isthm
Ascending aorta
Descending aorta
Aortic root
Aortic hiatus
Abdominal aorta

Fig. 2: Ascending thoracic aorta extends from the root to the origin of the right brachiocephalic artery. The aortic root is the first segment of the ascending aorta, containing: the valve, the annulus and the sinuses. Aortic arch starts at the level of the right brachiocephalic artery with its distal boundary being the attachment of the ligamentum arteriosum. The arch may then be subdivided in proximal (from the right brachiocephalic artery to the left subclavian artery) and distal (until the ligamentum arteriosum attachment). The descending aorta extends from the attachment of the ligamentum arteriosum to the aortic hiatus of the diaphragm. The isthmus is narrower portion of the proximal descending aorta.

© Radiologia, Centro Hospitalar e Universitário de Coimbra - Guimarães/PT

Fig. 3: Contrast-enhanced CT demonstrating anintimal flap exteding to the origin of the superior mesenteric artery, leading to static obstruction.

© Radiologia, Centro Hospitalar e Universitário de Coimbra - Guimarães/PT

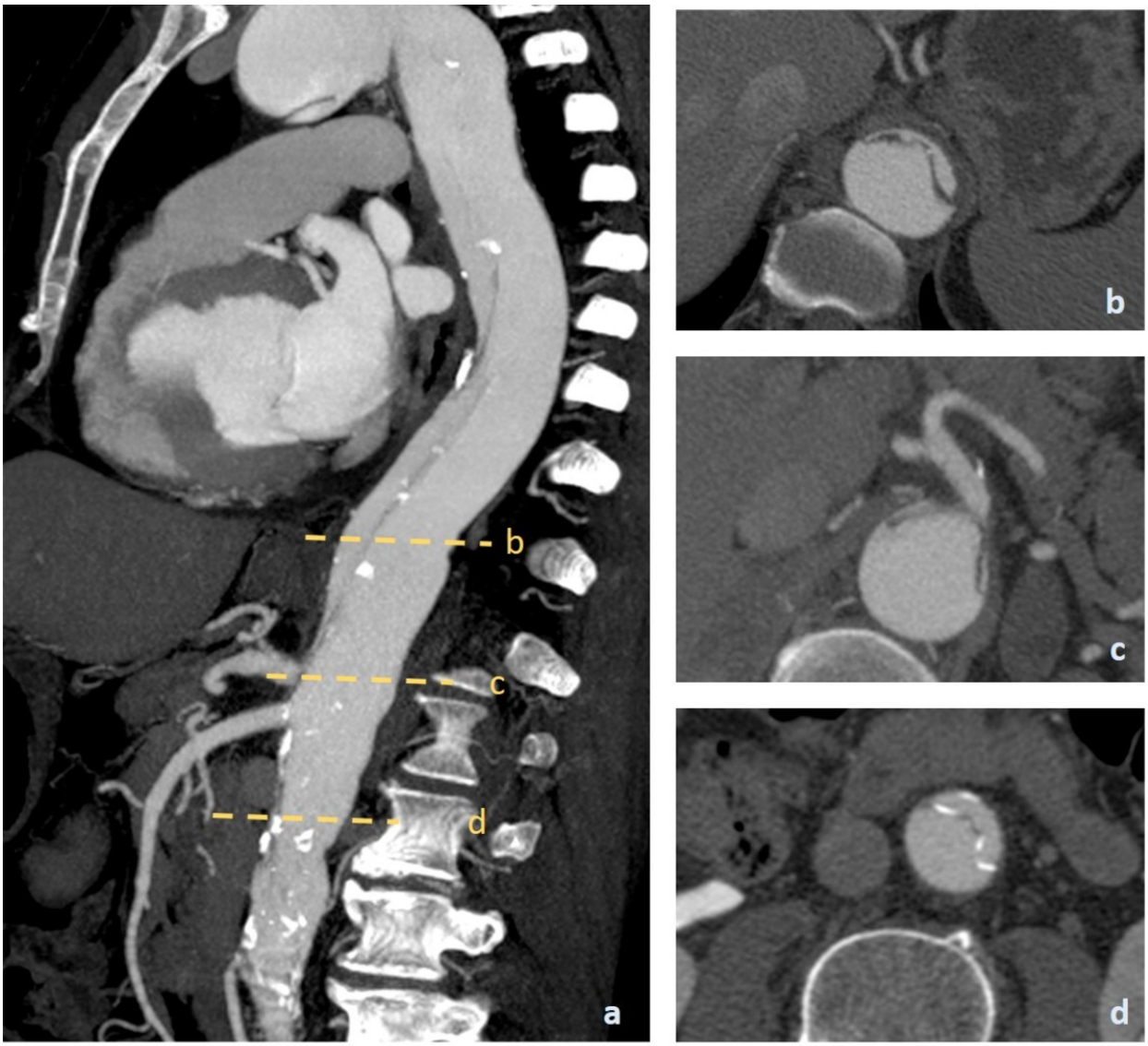

Fig. 4: Contrast enhanced CT in a patient with type A aortic dissection. In the sagital MIP (a), the true lumen can be recognized anteriorly, with the false lumen occupying most of the aortic diameter. Intimal calcifications help in the recognition of the true lumen. Even tough the celial trunk arises from the true lumen (seen in a and c), the increased pressure of the false lumen cause the intimal flap to protrude forward, reducing the calibre of the true lumen and blocking the ostium of the celiak trunk (c). The same mechanism is seen at the emergence of the superior mesenteric artery (a).

© Radiologia, Centro Hospitalar e Universitário de Coimbra - Guimarães/PT

Findings and procedure details

A. Aortic dissection

Dissection represents 70% of AAS and results from a tear of the aortic intimal layer, usually preceded by medial wall degeneration and cystic medial necrosis, with blood gaining access to the media from the aortic lumen. This creates two lumina - the true lumen which communicates with the nondissected lumen and the false lumen. The newly created false lumen becomes filled with blood and might have a similar or even greater pressure than the true lumen. This pressure difference may cause the true lumen to collapse and the dissection to extend, either on an antegrade or retrograde directions. The false lumen may thrombose, recommunicate with the true lumen or rupture into pericardial, pleural or peritoneal cavities.

An important complication of aortic dissection is branch obstruction, which can be static or dynamic. In the first mechanism, static obstruction, the flap enters the branch-vessel origin without a re-entry point (Fig. 3). This results in a rise of pressure in this branch and thrombus formation, leading to focal stenosis and eventual end-organ ischemia.

Fig. 3: Contrast-enhanced CT demonstrating anintimal flap exteding to the origin of the superior mesenteric artery, leading to static obstruction.
References: Radiologia, Centro Hospitalar e Universitário de Coimbra - Guimarães/PT

Dynamic obstruction occurs when the intimal flap covers a branch of the aorta like a curtain and can also lead to ischemia (Fig. 4).

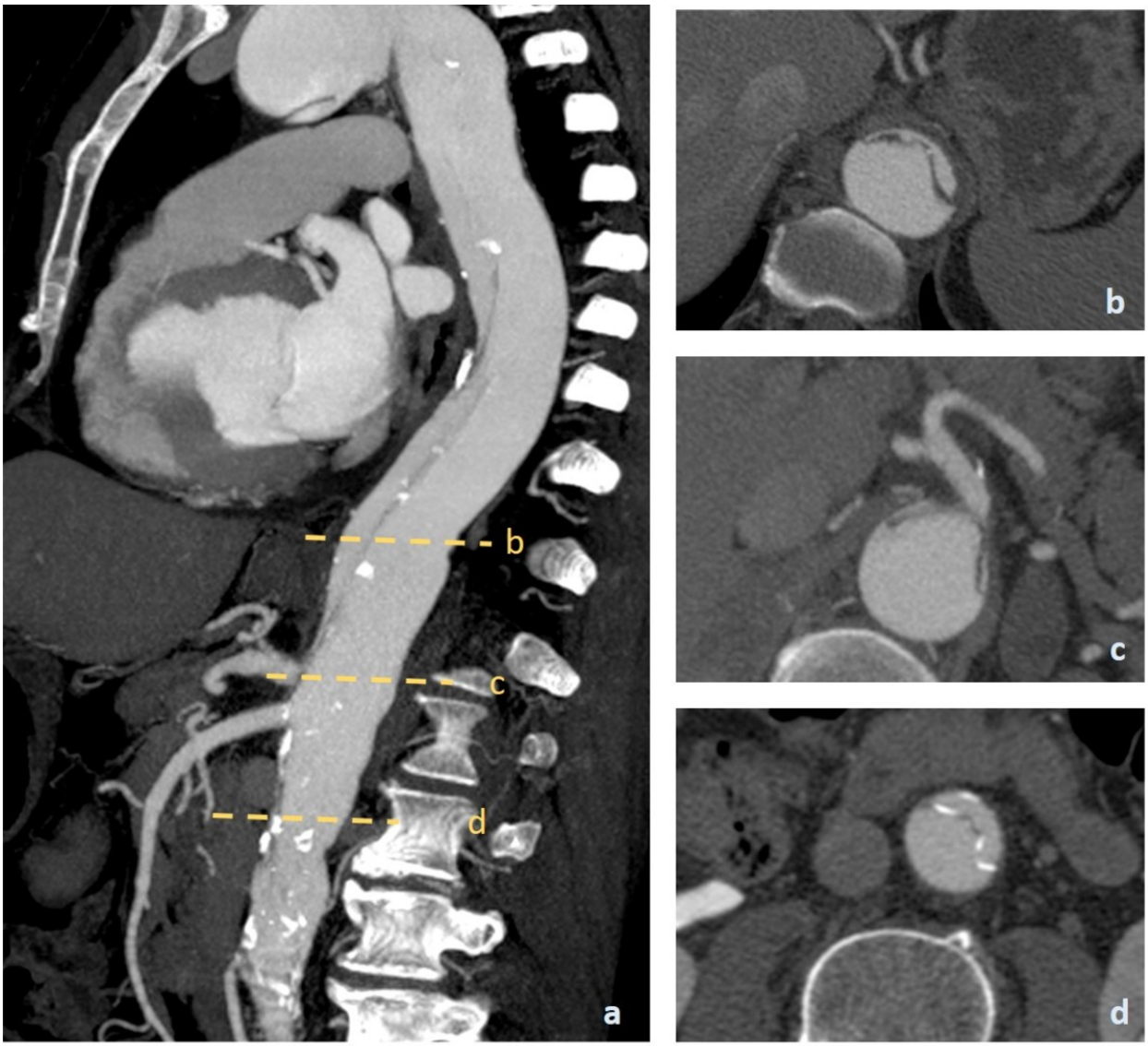

Fig. 4: Contrast enhanced CT in a patient with type A aortic dissection. In the sagital MIP (a), the true lumen can be recognized anteriorly, with the false lumen occupying most of the aortic diameter. Intimal calcifications help in the recognition of the true lumen. Even tough the celial trunk arises from the true lumen (seen in a and c), the increased pressure of the false lumen cause the intimal flap to protrude forward, reducing the calibre of the true lumen and blocking the ostium of the celiak trunk (c). The same mechanism is seen at the emergence of the superior mesenteric artery (a).
References: Radiologia, Centro Hospitalar e Universitário de Coimbra - Guimarães/PT

Long-evolution hypertension is the most frequent factor predisposing aortic dissection, but other causes can also be identified (Fig. 5).

Causes of aortic dissection
Long-evolution hypertension
Connective tissue disorder (Marfan syndrome, Loeys-Dietz syndrome, Turner syndrome, etc.)
Congenital aortic valvular defects
Auto-imune/ infection
Aortic coarctation
Cocaine use
Pregnancy
Trauma
Iatrogenic (previous cardiac or valvular surgery)

Fig. 5: List of the main causes of aortic dissection.
References: Radiologia, Centro Hospitalar e Universitário de Coimbra - Guimarães/PT

Dissection can be separated according to its evolution in acute and chronic forms (Fig. 6), depending whether the symptoms last less or more than 2 weeks.

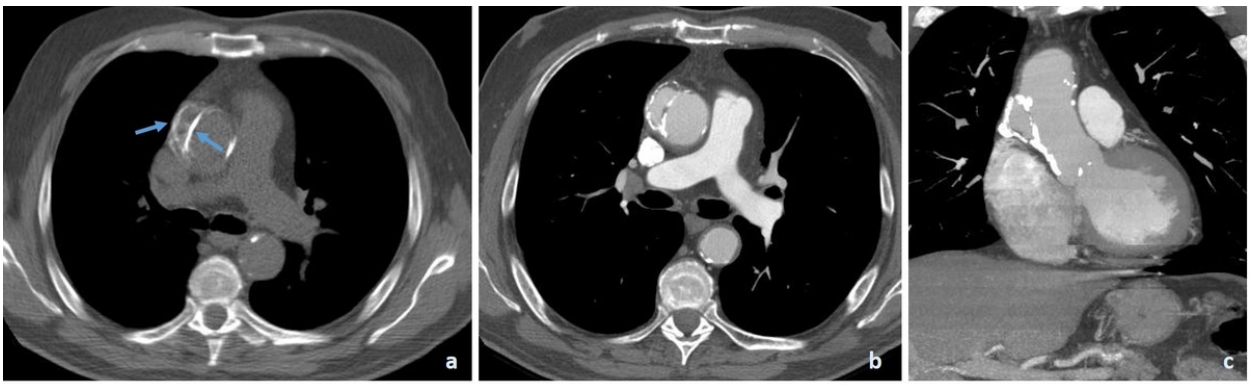

Fig. 6: Patient with a chronic dissection in the ascending aorta. CT demonstrated wall calcifications surrouding the false lumen (arrows), indicative of a chronic process.
References: Radiologia, Centro Hospitalar e Universitário de Coimbra - Guimarães/PT

The right lateral wall of the ascending aorta (immediately distal to Valsalva sinus) and the proximal segment of the descending thoracic aorta are the sites of maximum stress and therefore the most common sites of intimal tears.

A. 1. Imaging findings

Unenhanced CT might be relevant in diagnosing aortic dissection by showing displacement of intimal calcifications and high attenuation of the false lumen.

Contrast-enhanced CT allows the identification of the intimal flap. The distinction between the true and the false lumen is important due to the possibility of endovascular treatment. The CT report should then include which major branches of the aorta arise from the false lumen as well as the entry point location. There are several imaging signs used to identify the true and the false lumen correctly. Strands of low attenuation soft tissue might be seen on the false lumen, representing the incompletely sheared layer of the media - the **cobweb sign** (Fig. 7).

Fig. 7: Contrast-enhanced CT demonstrating aortic dissection in the descending aorta. The false lumen occupies most of the aortic lumen, with the true lumen mostly

compressed anterior and laterally. In the false lumen filliform strands of media are seen (arrow) and when present identify this lumen - cobweb sign.
References: Radiologia, Centro Hospitalar e Universitário de Coimbra - Guimarães/PT

The false lumen usually displays a larger area, shows delayed enhancement in comparison to the true lumen and might display the **beak sign** when at the edge of the lumen (Fig. 8).

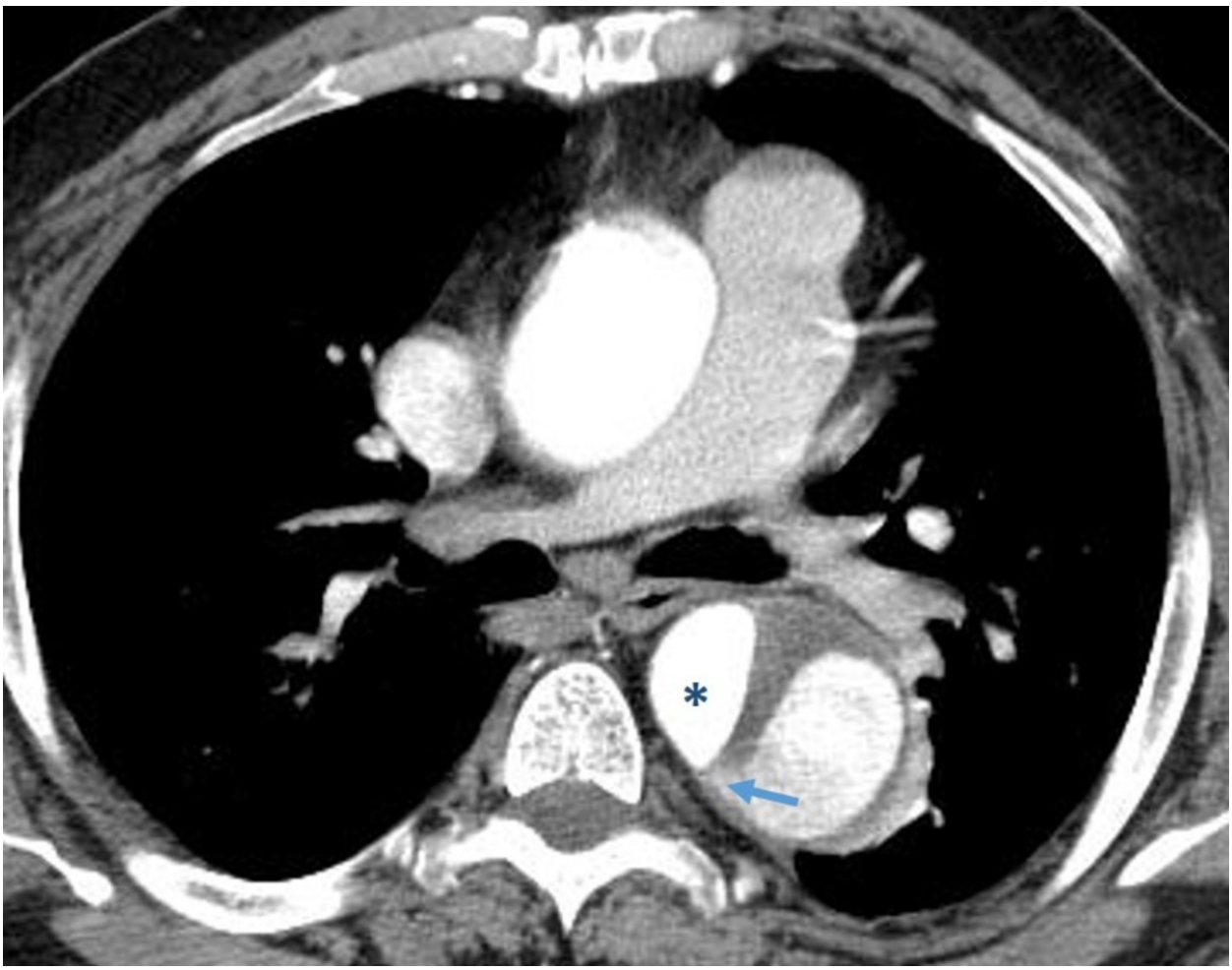

Fig. 8: The beak sign (arrow) identifies the false lumen. It refers to the propagating wedge hematoma in the false lumen as it cleaves a space and separates the intima. The true lumen (asterisk) may be recognized from the false lumen by its smaller volume and intense early opacification.
References: Radiologia, Centro Hospitalar e Universitário de Coimbra - Guimarães/PT

It may be occluded by a thrombus if chronic and usually shows delayed enhancement. It is frequently the origin of the left renal artery.

Less frequently, there can be a dissection variant in which multiple flaps and multiple false lumina are seen - multibarreled aortic dissection (Fig. 9).

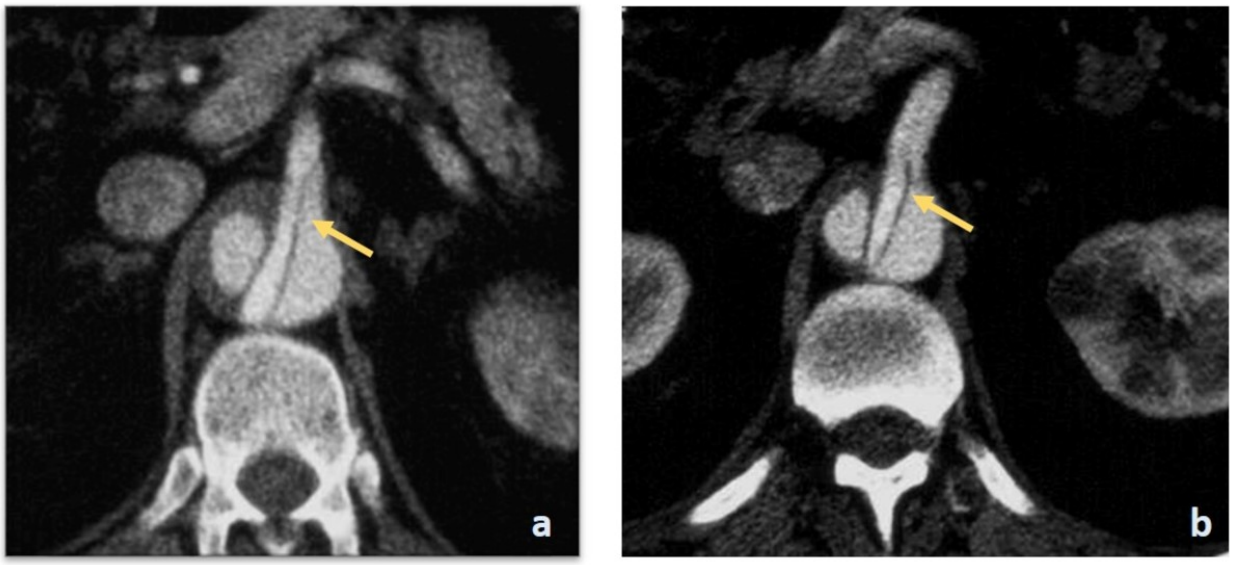

Fig. 9: Contrast-enhanced CT in a rare cases of a multibarreled aortic dissection can. Two false lumina are seen, with one intimal flap extending to the celiac trunk (arrow in a) and the superior mesenteric artery (arrow in b).
References: Radiologia, Centro Hospitalar e Universitário de Coimbra - Guimarães/PT

The true lumen might be seen in continuity with the nondissected segments of the aorta, is surrounded by calcifications (if present) and is frequently smaller. Most commonly, the true lumen is the origin of the celiac trunk, superior mesenteric artery and the right renal artery.

Intimointimal intussusception is a circumferential type of aortic dissection which progresses like a windsock (Fig. 10). In these cases, the intimal tear is located near the coronary ostia and the inner lumen is the true lumen.

Fig. 10: Contrast-enhanced CT in a patient with intimo-intimal intussusception.
A special type of aortic dissection is seen with circunferential separation of the intimomedial flap from the aortic wall. The inner lumen is the true lumen (asterisk).
References: Radiologia, Centro Hospitalar e Universitário de Coimbra - Guimarães/PT

The spiral shape of the dissection and the regular borders of the flap are useful in the distinction between a thrombosed false lumen and an aneurysm with a peripheral thrombus.

A. 2. Classification

Stanford classification for aortic dissection is simple and the most widely used classification system, with an immediate correspondence to the therapeutic approach. It

is determined by the origin of the intimal tear. Stanford type A (2/3 of dissections) involves the proximal thoracic aorta or the aortic arch. Dissection of the aorta distal to the left subclavian origin is classified as Stanford B (Fig. 11).

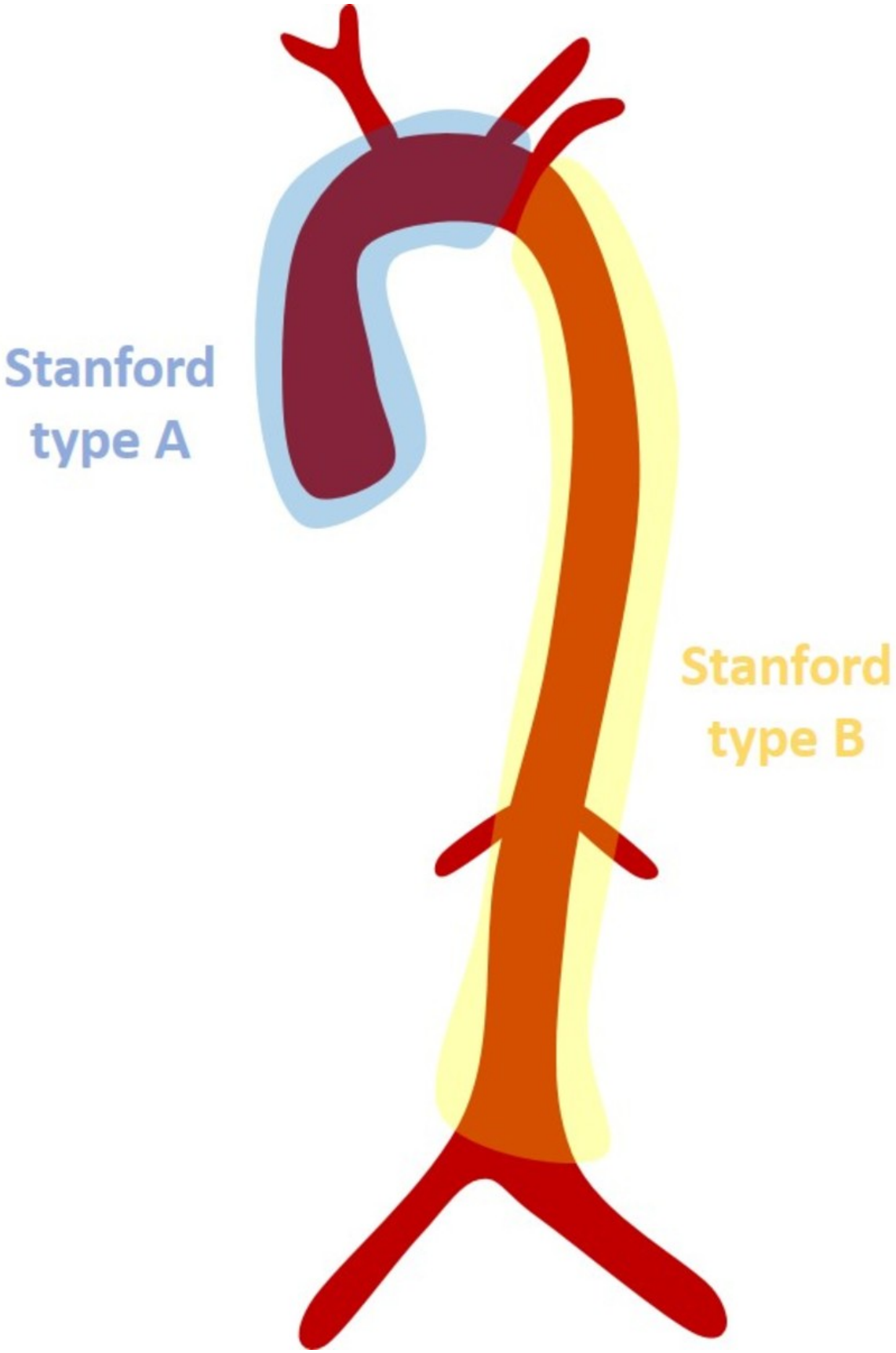
Stanford
type A
Stanford
type B

Fig. 11: Stanford classification for aortic dissection. It is determined by the origin of the intimal tear. Stanford type A involves the proximal thoracic aorta or the aortic arch. Dissection of the aorta distal to the left subclavian origin is classified as Stanford B.
References: Radiologia, Centro Hospitalar e Universitário de Coimbra - Guimarães/PT

B. Intramural hematoma (IMH)

Intramural hematoma is considered by some authors to be a subtype of aortic dissection, representing 5-20% of AAS. According to them, a hematoma confined to the layer of the aorta might be due to microscopic tears on the intima, contrary to the earlier belief that they resulted from rupture of the vasa vasorum of the medial layer, with an intact intima. Intramural hematoma might lead to aortic wall infarction and subsequent dissection. The risk of progression to dissection is 40% in the first month and 20% thereafter. It can also progress to rupture or be reabsorbed.

B. 1. Imaging findings

Performing an unenhanced CT is mandatory in the suspicion of intramural hematoma since the contrast may obscure it. This acquisition might reveal a high attenuating crescent-shaped collection on the aortic wall that might compress the aortic lumen (Fig. 12).

Fig. 12: Non-contrasted CT revealing an hyperdense collection in the left wall of the aorta (asterisk in a), without contour deformity. After contrast injection (b) no contrast leak is evidente, findings compatible with the diagnosis of intramural hematoma.
References: Radiologia, Centro Hospitalar e Universitário de Coimbra - Guimarães/PT

Some features are important to notice when reporting an intramural hematoma. A thickness of the hematoma superior to 2 cm, compression of the true lumen or pericardial/ pleural effusion are important signs to look for since they may suggest a risk for progression to dissection.

Classification of IMH is done according to the Stanford system of aortic dissection into types A and B.

C. Penetrating atherosclerotic ulcer (PAU)

Ulceration of an atherosclerotic plaque with erosion of the intima leads the blood accessing the medial layer of the aorta, producing an hematoma that can develop to aneurysm and rupture. Some authors defend that most saccular aneurysms of the aorta are produced by PAU. This pathology is characteristic of elderly patients with advanced atherosclerosis (frequently with concomitant coronary disease, peripheral arterial disease and abdominal aortic aneurysms). PAU may also occur in young individuals with connective tissue disorders of after rupture of a mycotic plaque.

PAU is more common in the aortic arch or descending aorta, occurring rarely in the ascending aorta, where the rapid flow of blood provides protection against the formation of atherosclerotic plaques.

C. 1. Imaging findings

Extensive atherosclerotic disease is usually a feature of patients with PAU and will be demonstrated on unenhanced CT scan. After contrast injection, an outpouching of the aortic wall with irregular edges and intimal calcification surrounding the base of the ulcer allows the diagnosis (Fig. 13).

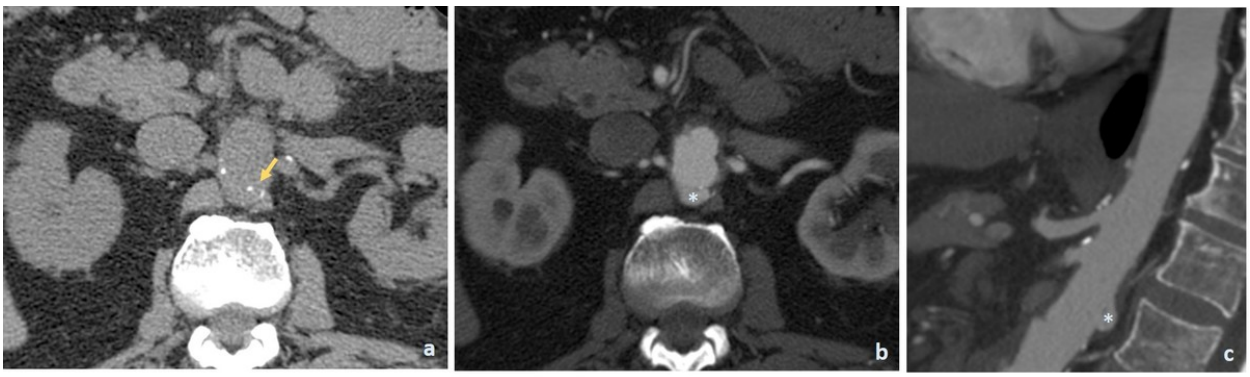

Fig. 13: Non-enhanced CT on the axial plane demonstrating extensive atherosclerosis in the posterior aortic wall (arrow in a). After contrast injection a posterior pouch-like protrusion of the aorta in absence of a intimal flap is noted (asterisk in b and c).
References: Radiologia, Centro Hospitalar e Universitário de Coimbra - Guimarães/PT

When a rupture occurs, it is difficult to distinguish between a ruptured aneurysm and a complicated atherosclerotic ulcer. In both cases, immediate surgical treatment is required.

Nonpenetrating ulcers are confined to the intima and frequently asymptomatic (Fig. 14).

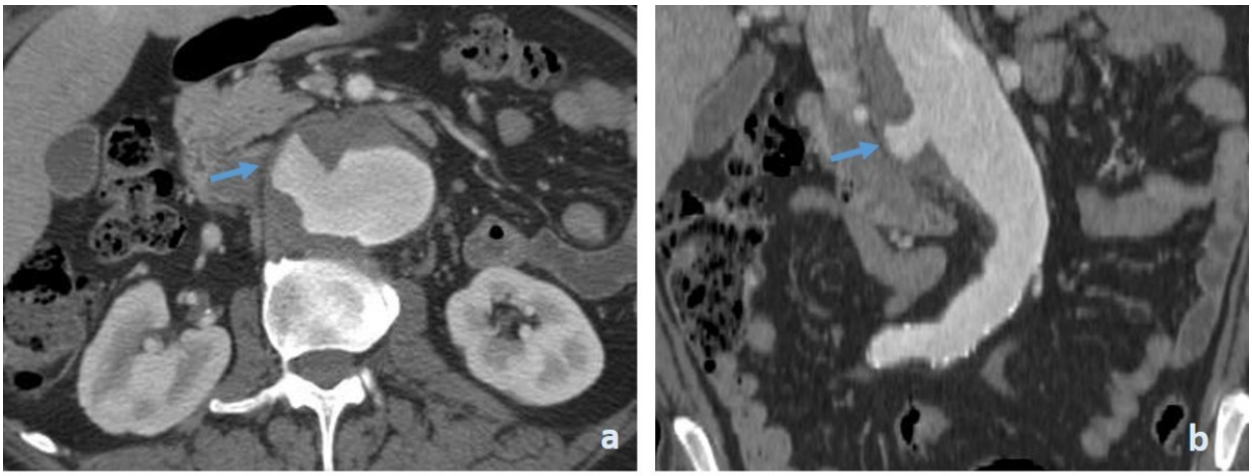

Fig. 14: Patient with a nonpenetrating ulcer. There is a thrombus with focal ulceration (arrows in a and b), but no contrast material is extending beyond level of intima and no intramural hematoma is present. The patient was assymptomatic.
References: Radiologia, Centro Hospitalar e Universitário de Coimbra - Guimarães/PT

D. Treatment of acute aortic syndromes

Acute aortic syndromes involving ascending aorta and the aortic arch (Stanford A) require emergency surgery, either convencional oy endovascular. The goal is to avoid lethal complications, such as hemopericardium/hemothorax, extension to the coronary arteries or the valvular ring. If untreated, they have over 50% mortality within 48 hours.

Acute aortic syndromes involving the descending aorta (Stanford B) are primarily treated medically. Medical treatment is designed to limit propagation of the dissection, reducing the forces applied to the fragile wall. Thus, it is essential to control systolic arterial pressure to 100-120 mmHg and cardiac rate to 60-80 bpm. B-blockers are the first line

medications to be used, but angiotensin II antagonists might also have a role in aortic remodeling and thus may also be used. Endovascular treatment with aortic endoprothesis implantation and eventual branch angioplasty are indicated for complicated AAS (Fig. 15).

Complicated Acute aortic syndrome
Imminent rupture (hematoma adjacent to the aorta)
Malperfusion (limb or organ)
Untreatable pain
Non-controlable hypertension
Rapid growth (>10 mm per year)

Fig. 15: Signs of complicated acute aortic syndrome
References: Radiologia, Centro Hospitalar e Universitário de Coimbra - Guimarães/PT

Recent studies suggest that patients with type B AAS, but with increased risk of progressive disease (elevated aortic diameter, increased false lumen, Marfan syndrome, COPD, age superior to 60 years and female sex) might also benefit from endovascular treatment.

E. Complications

E. 1. Thoracic complications

Hyperattenuating collections in the mediastinum, pericardium or pleural cavity on unhenhanced CT scans may be a clue to thoracic aortic rupture. After contrast injection the irregularity in the aortic wall or direct leak of contrast should be sought in order to make this diagnosis.

Acute pericardial effusion in a patient with type A aortic dissection is related to a high mortality due to the risk of cardiac tamponade (Fig. 16).

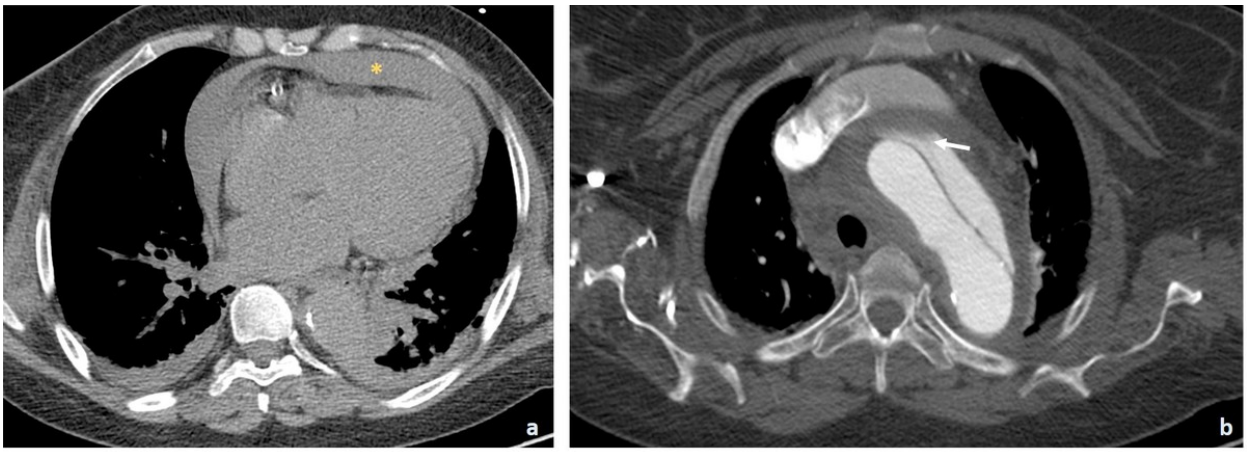

Fig. 16: Non-contrasted CT demonstrating spontaneously hyperdense pericardial fluid, consistent with hemopericardium (asterisk in a). Bilateral pleural fluid is also seen. After contrast injection signs of Stanford type A aortic dissection are seen, with parcial trombosis of the false lumen (arrow in b).
References: Radiologia, Centro Hospitalar e Universitário de Coimbra - Guimarães/PT

E. 2. Neurologic complications

Aortic dissection extending to the supraaortic trunks is not frequent (5-10% of dissections), but should be reported since it may lead to cerebral ischemia (Fig 17).

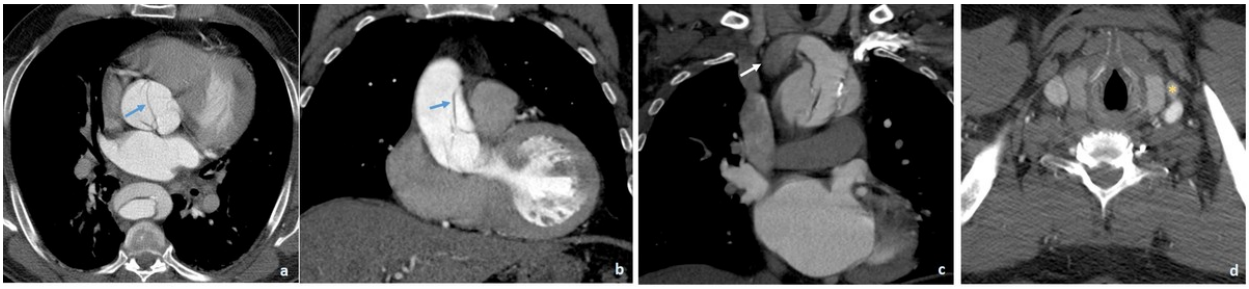

Fig. 17: CT revealing and intimal flap in the ascending thoracic aorta (arrows in a and b) exteding to the descending aorta. Extension of the intimal flap to the brachiocephalic arteryand trombosis isseen (arrow in b showing the thrombus in the brachiocephalic artery and c with signs of carotid artery thrombosis - asterisk in the left carotid artery, while the right artery is not seen).
References: Radiologia, Centro Hospitalar e Universitário de Coimbra - Guimarães/PT

The presence of neurologic symptoms will guide the surgical approach since the absence of symptoms may not warrant aortic arch replacement due to its high mortality.

E. 3. Abdominal or limb complications

Obstruction of major abdominal aortic branches occurs either due to static or dynamic mechanisms.

The morphology of the true lumen might also be an indicator of the risk of aortic-branches ischemia if this lumen shows a crescent or concave shape towards the false lumen, which can result from low pressure.

Extension of dissection to the iliac vessels may also represent a risk for leg ischemia (Fig. 18).

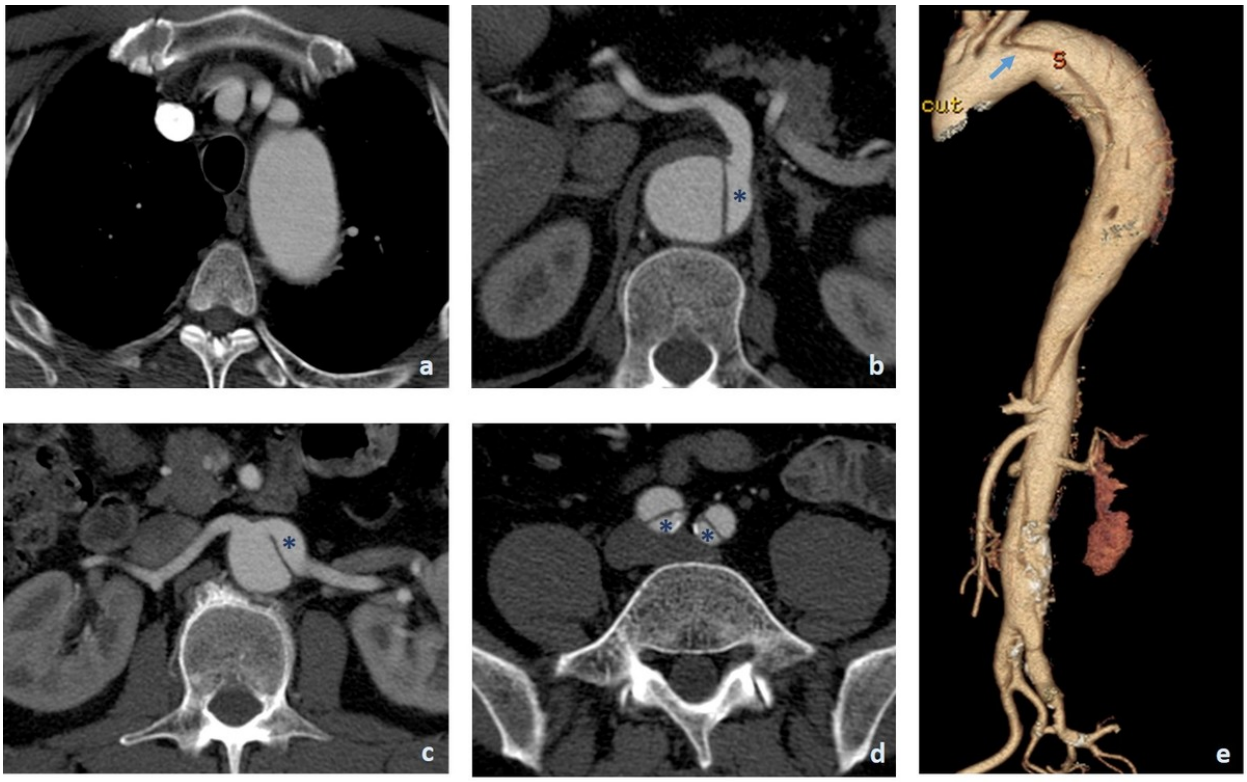

Fig. 18: Contrast-enhanced axial CT demonstrating aortic dissection Stanford type B (intimal flap does not extend to the origin of the left subclavian artery - a and e). The celiak trunk and the mesenteric artery emerge from the true lumen (asterisk in b), as well as the left renal artery (asterisk in c). The right renal artery emerges from the false lumen (c). The dissection extends beyond aortic bifurcation to involve both common iliac arteries.
References: Radiologia, Centro Hospitalar e Universitário de Coimbra - Guimarães/PT

E. 4. Aortoenteric fistulas

Aortic fistulas to the gastrointestinal tract can either be primary or secondary. Primary fistulas occur in patients with voluminous aortic aneurysmsm, mycotic aneurysms or by tumoral invasion (Fig. 19).

Fig. 19: CT of a 71 years-old male that presented to the emergency departments with recente episodes of hematemesis. Endoscopy revealeda defect in the posterior wall of the esopaghus in an aderente thrombus on the wall. Non-contrast enhanced CT demonstrated extensive aortic calcifications and an heterogenous collection with spoutaneously hyperdense areas lateral to the descending aorta, consistent with hematoma with recente bleeding (arrow in a). Contrast leak is seen to the collection from the aorta (b). This pouch-like protusion is surrounded by atherosclerotic plaques (arrows in c). The esophagus is deviated laterally (asterisk in c) and is involved by this hematic collection. The association of CT and endoscopic findings is sugestive of aorto-esophageal fistula.
References: Radiologia, Centro Hospitalar e Universitário de Coimbra - Guimarães/PT

Secondary fistulas are more common and appear in patients submitted to aortic revascularization procedures. The fistula pathogenesis can be from mechanical erosion or by infection. The duodenum (especially the 3rd and 4th segments) is most frequently involved, although other segments may also be involved, such as the esophagus. The presence of abdominal pain associated with hematemesis or melena might be a clue to the diagnosis.

Images for this section:

Causes of aortic dissection
Long-evolution hypertension
Connective tissue disorder (Marfan syndrome, Loeys-Dietz syndrome, Turner syndrome, etc.)
Congenital aortic valvular defects
Auto-imune/ infection
Aortic coarctation
Cocaine use
Pregnancy
Trauma
Iatrogenic (previous cardiac or valvular surgery)

Fig. 5: List of the main causes of aortic dissection.

© Radiologia, Centro Hospitalar e Universitário de Coimbra - Guimarães/PT

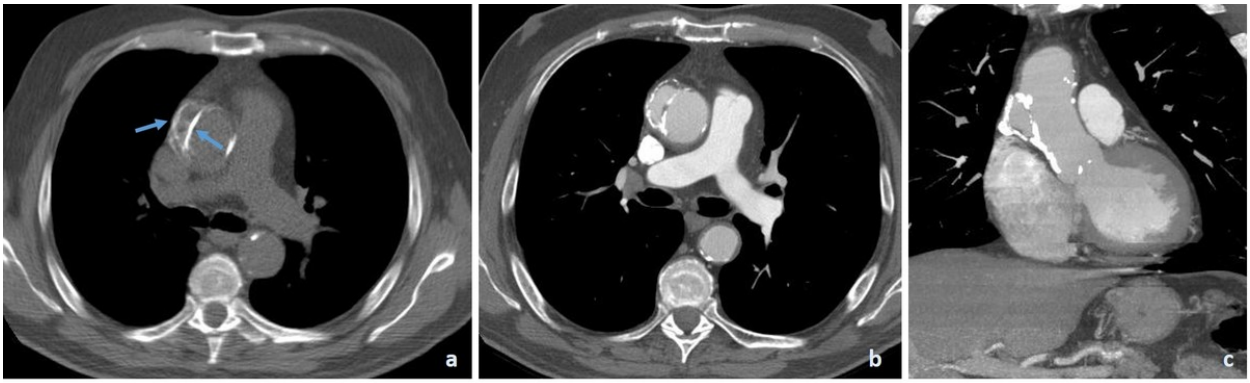

Fig. 6: Patient with a chronic dissection in the ascending aorta. CT demonstrated wall calcifications surrouding the false lumen (arrows), indicative of a chronic process.

© Radiologia, Centro Hospitalar e Universitário de Coimbra - Guimarães/PT

Fig. 7: Contrast-enhanced CT demonstrating aortic dissection in the descending aorta. The false lumen occupies most of the aortic lumen, with the true lumen mostly compressed anterior and laterally. In the false lumen filliform strands of media are seen (arrow) and when present identify this lumen - cobweb sign.

© Radiologia, Centro Hospitalar e Universitário de Coimbra - Guimarães/PT

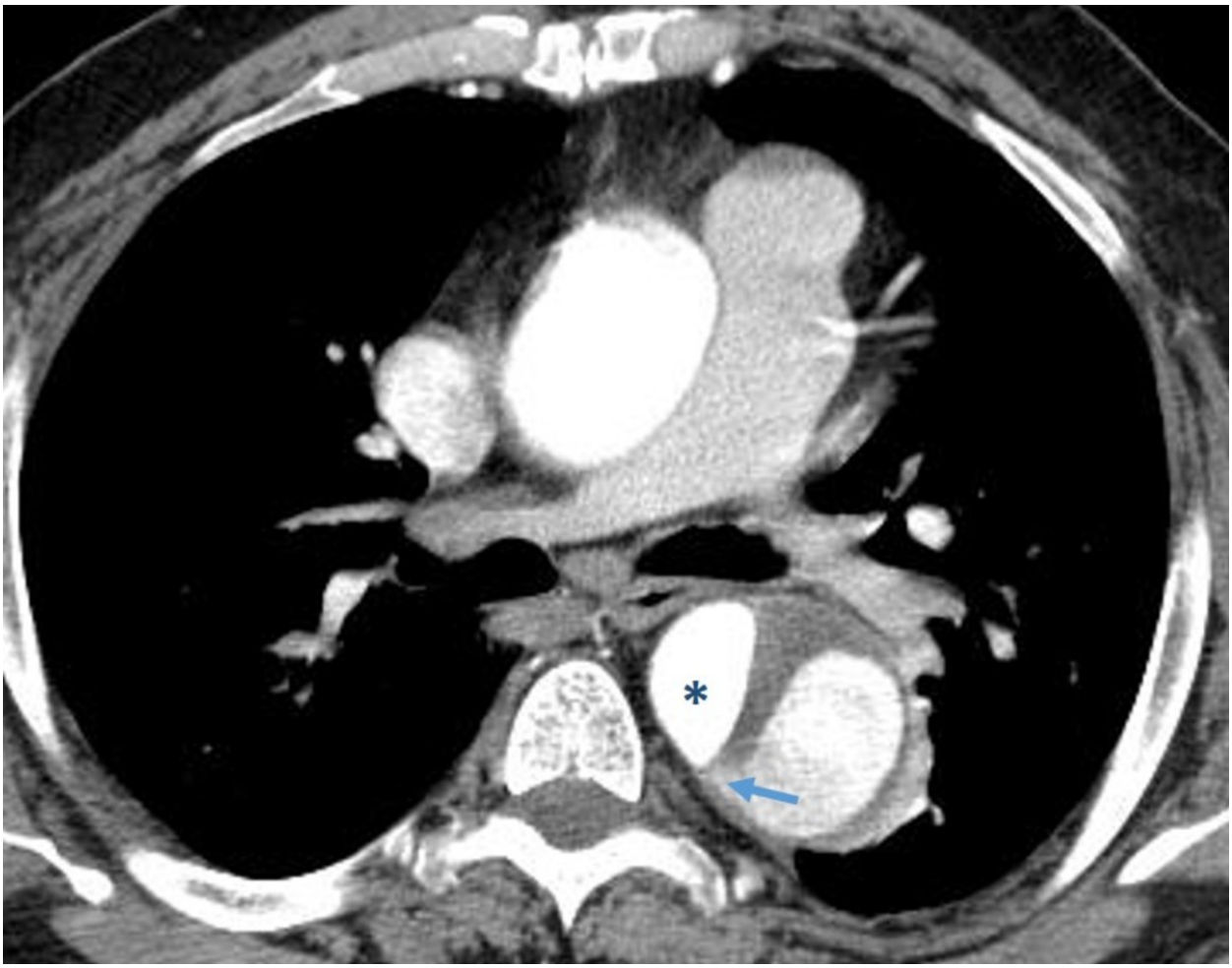

Fig. 8: The beak sign (arrow) identifies the false lumen. It refers to the propagating wedge hematoma in the false lumen as it cleaves a space and separates the intima. The true lumen (asterisk) may be recognized from the false lumen by its smaller volume and intense early opacification.

© Radiologia, Centro Hospitalar e Universitário de Coimbra - Guimarães/PT

Fig. 10: Contrast-enhanced CT in a patient with intimo-intimal intussusception. A special type of aortic dissection is seen with circunferential separation of the intimomedial flap from the aortic wall. The inner lumen is the true lumen (asterisk).

© Radiologia, Centro Hospitalar e Universitário de Coimbra - Guimarães/PT

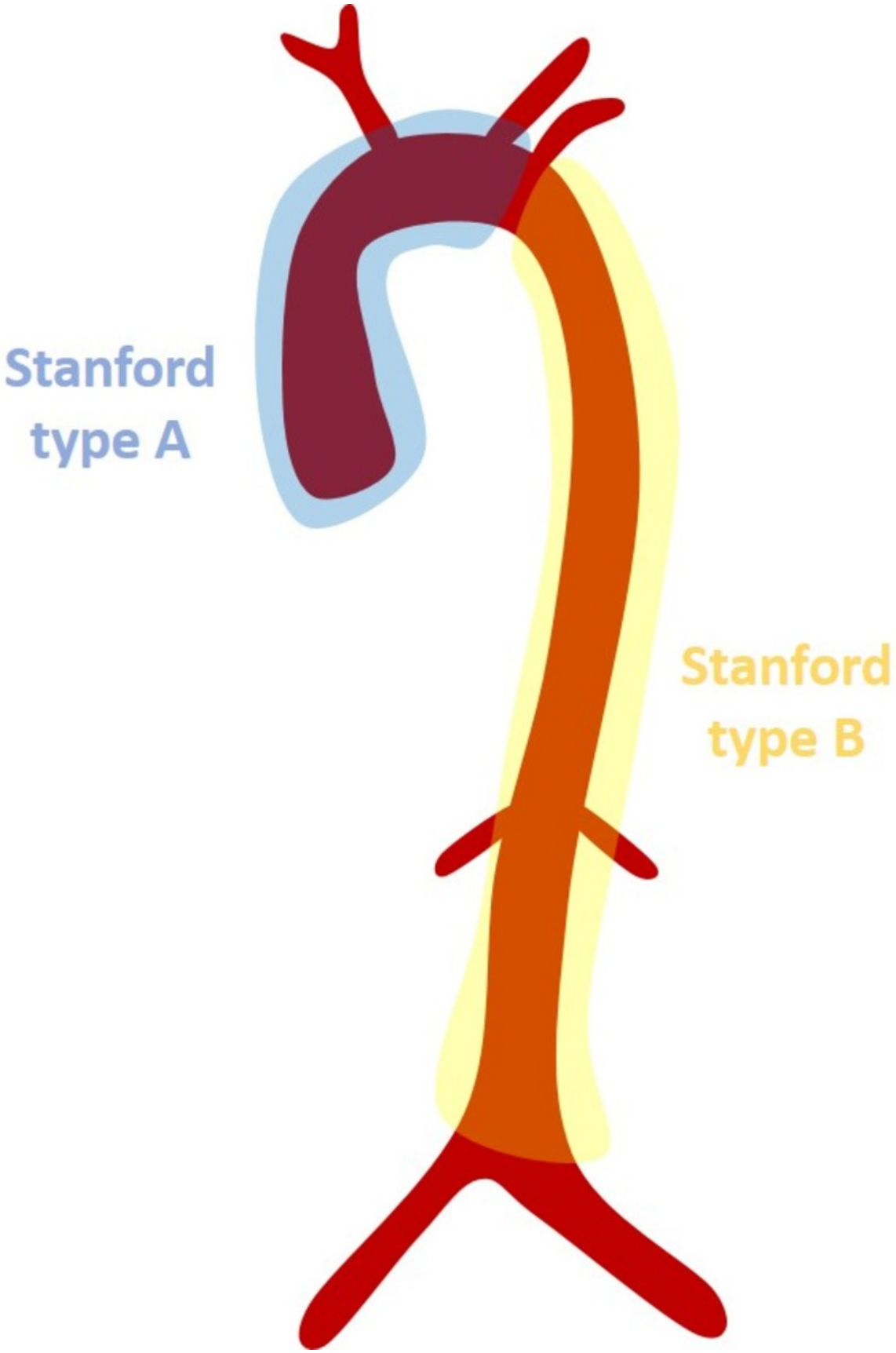
Stanford
type A
Stanford
type B

Fig. 11: Stanford classification for aortic dissection. It is determined by the origin of the intimal tear. Stanford type A involves the proximal thoracic aorta or the aortic arch. Dissection of the aorta distal to the left subclavian origin is classified as Stanford B.

© Radiologia, Centro Hospitalar e Universitário de Coimbra - Guimarães/PT

Fig. 12: Non-contrasted CT revealing an hyperdense collection in the left wall of the aorta (asterisk in a), without contour deformity. After contrast injection (b) no contrast leak is evidente, findings compatible with the diagnosis of intramural hematoma.

© Radiologia, Centro Hospitalar e Universitário de Coimbra - Guimarães/PT

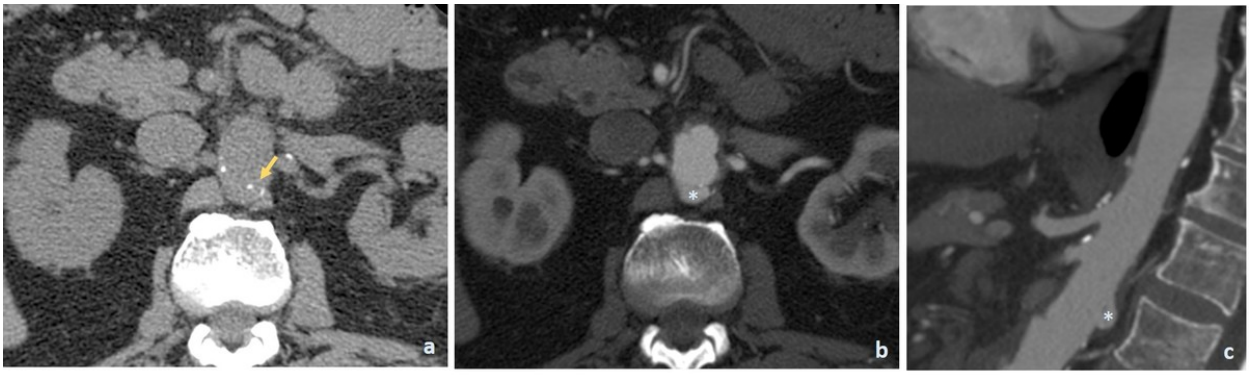

Fig. 13: Non-enhanced CT on the axial plane demonstrating extensive atherosclerosis in the posterior aortic wall (arrow in a). After contrast injection a posterior pouch-like protrusion of the aorta in absence of a intimal flap is noted (asterisk in b and c).

© Radiologia, Centro Hospitalar e Universitário de Coimbra - Guimarães/PT

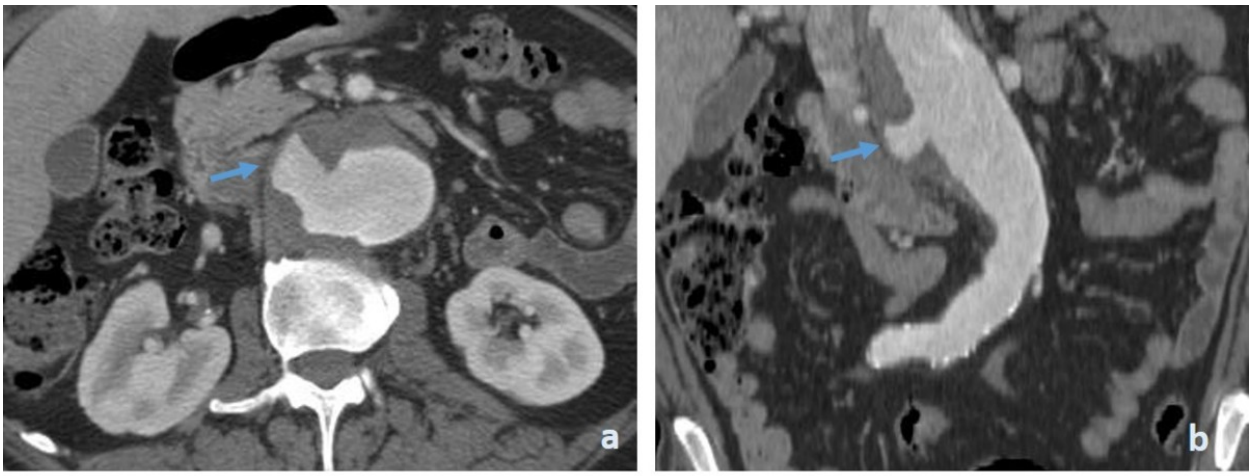

Fig. 14: Patient with a nonpenetrating ulcer. There is a thrombus with focal ulceration (arrows in a and b), but no contrast material is extending beyond level of intima and no intramural hematoma is present. The patient was assymptomatic.

© Radiologia, Centro Hospitalar e Universitário de Coimbra - Guimarães/PT

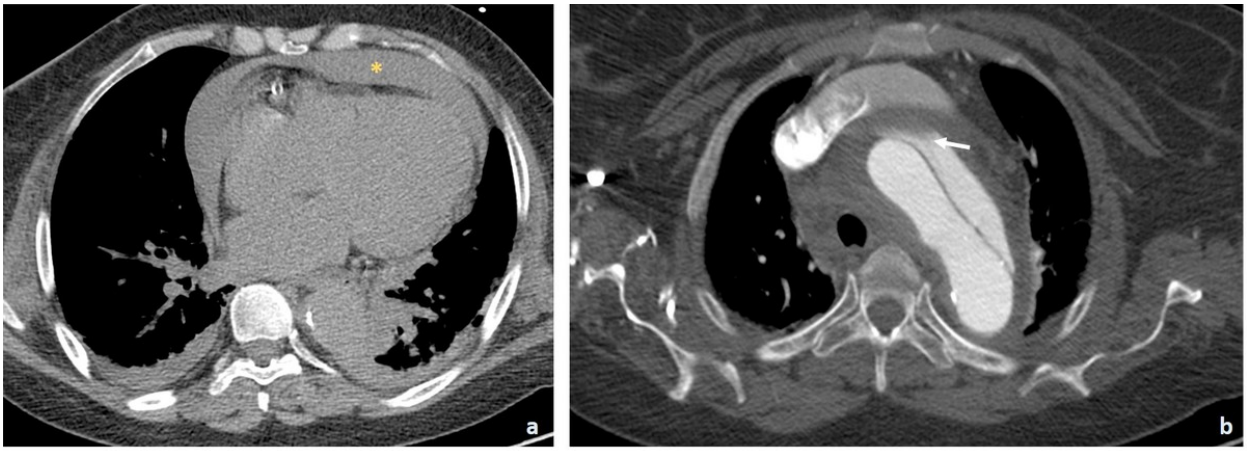

Fig. 16: Non-contrasted CT demonstrating spontaneously hyperdense pericardial fluid, consistent with hemopericardium (asterisk in a). Bilateral pleural fluid is also seen. After contrast injection signs of Stanford type A aortic dissection are seen, with parcial trombosis of the false lumen (arrow in b).

© Radiologia, Centro Hospitalar e Universitário de Coimbra - Guimarães/PT

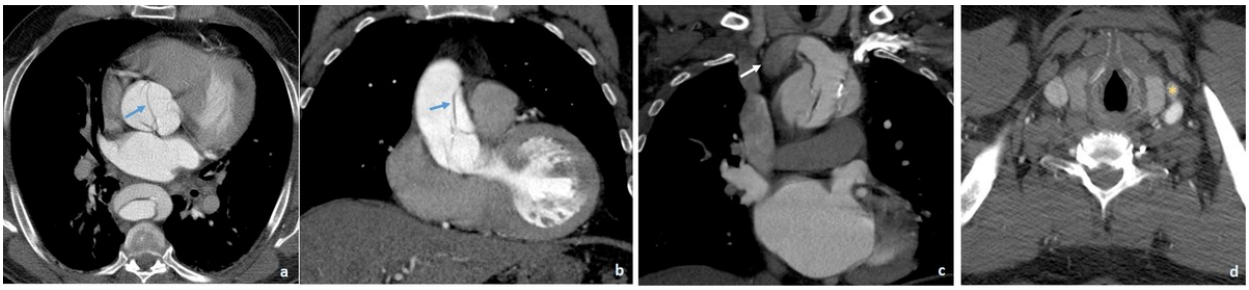

Fig. 17: CT revealing and intimal flap in the ascending thoracic aorta (arrows in a and b) exteding to the descending aorta. Extension of the intimal flap to the brachiocephalic arteryand trombosis isseen (arrow in b showing the thrombus in the brachiocephalic artery and c with signs of carotid artery thrombosis - asterisk in the left carotid artery, while the right artery is not seen).

© Radiologia, Centro Hospitalar e Universitário de Coimbra - Guimarães/PT

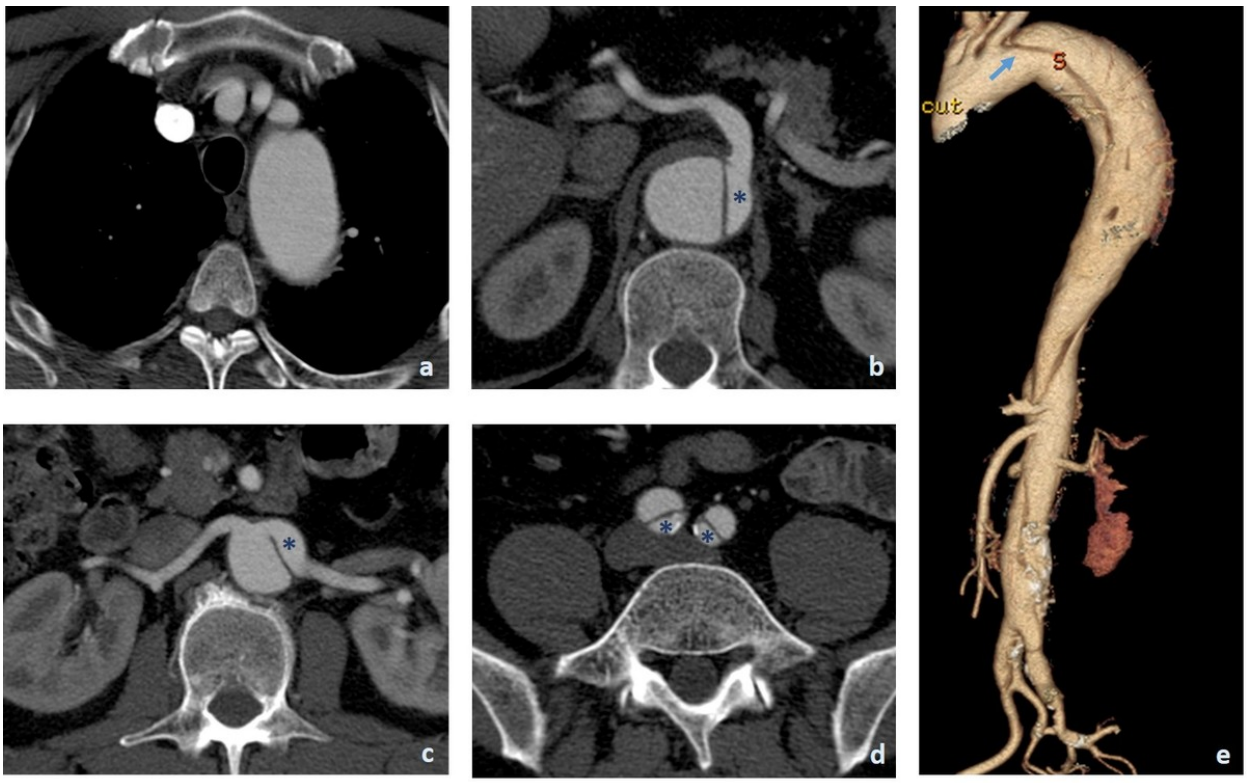

Fig. 18: Contrast-enhanced axial CT demonstrating aortic dissection Stanford type B (intimal flap does not extend to the origin of the left subclavian artery - a and e). The celiak trunk and the mesenteric artery emerge from the true lumen (asterisk in b), as well as the left renal artery (asterisk in c). The right renal artery emerges from the false lumen (c). The dissection extends beyond aortic bifurcation to involve both common iliac arteries.

© Radiologia, Centro Hospitalar e Universitário de Coimbra - Guimarães/PT

Fig. 19: CT of a 71 years-old male that presented to the emergency departments with recente episodes of hematemesis. Endoscopy revealeda defect in the posterior wall of the esopaghus in an aderente thrombus on the wall. Non-contrast enhanced CT demonstrated extensive aortic calcifications and an heterogenous collection with spoutaneously hyperdense areas lateral to the descending aorta, consistent with hematoma with recente bleeding (arrow in a). Contrast leak is seen to the collection from the aorta (b). This pouch-like protusion is surrounded by atherosclerotic plaques (arrows in c). The esophagus is deviated laterally (asterisk in c) and is involved by this hematic collection. The association of CT and endoscopic findings is sugestive of aorto-esophageal fistula.

© Radiologia, Centro Hospitalar e Universitário de Coimbra - Guimarães/PT

Complicated Acute aortic syndrome
Imminent rupture (hematoma adjacent to the aorta)
Malperfusion (limb or organ)
Untreatable pain
Non-controlable hypertension
Rapid growth (>10 mm per year)

Fig. 15: Signs of complicated acute aortic syndrome

© Radiologia, Centro Hospitalar e Universitário de Coimbra - Guimarães/PT

Conclusion

Acute aortic syndromes represent diagnostic challenges and therapeutic emergencies due to their high mortality. They are clinically indistinct, but present differentiating features on imaging studies. Multidetector CT is the method of choice for diagnosing AAS and its potential complications.

Optimizing the CT scan technique and knowing their different imaging appearance will allow AAS detection and the most adequate surgical management.

Personal information

References

- Batra P, et al. Pitfalls in the diagnosis of thoracic aortic dissection at CT angiography. Radiographics 2000; 20:309-320.

- Cooke JP, et al. The penetrating aortic ulcer: pathologic manifestations, diagnosis and management. Mayo Clin Proc 1988;63:718-725.

- Costello P, et al. Assessment of the thoracic aorta by spiral CT. AJR Am J Roentgenol 1992;158:1127-1130.

- Crawford ES. The diagnosis and management of aortic dissection. JAMA 1990;264:2537-2541.

- Castañer E, et al. CT in non traumatic acute aortic thoracic disease: typical and atypicl features and complications. Radiographics 2003; 23:S93-S110.

- Dake MD. Aortic intramural hematoma: current therapeutic strategy. Heart 2004;90:375-378.

- Erbel R, et al. Diagnosis and management of aortic dissection. Recommendations of the task force on aortic dissection, European Society of Cardiology. Eur Heart J 2001;22:1642-1681.

- Evangelista A, et al. Prognostic value of clinical and morphologic findings in short-term evolution of aortic intramural hematoma. Therapeutic implications. Eur Heart J 2004;25:81-87.

- Fisher ER, et al. Acute aortic dissecton: typical and atypical imaging features. Radiographics 1994;14:1263-1271.

- Kastan DJ, et al. Intimo-intimal intussusception: an unusual presentation of aortic dissection. AJR am J Roentgenol 1988;151:603-604.

- Maddu K. et al. Nontraumatic Acute Aortic Emergencies: Part 1, Acute Aortic Syndrome. AJR 2014;202: 656-665.

- Michelle M et al. Multidetector CT of Aortic Dissection: A Pictorial Review. Radiographics 2010; 30:445-460.

- Rakita D, et al. Spectrum of CT Findings in Rupture and Impending Rupture of Abdominal Aortic Aneurysms. Radiographics 2007; 27:497-507.